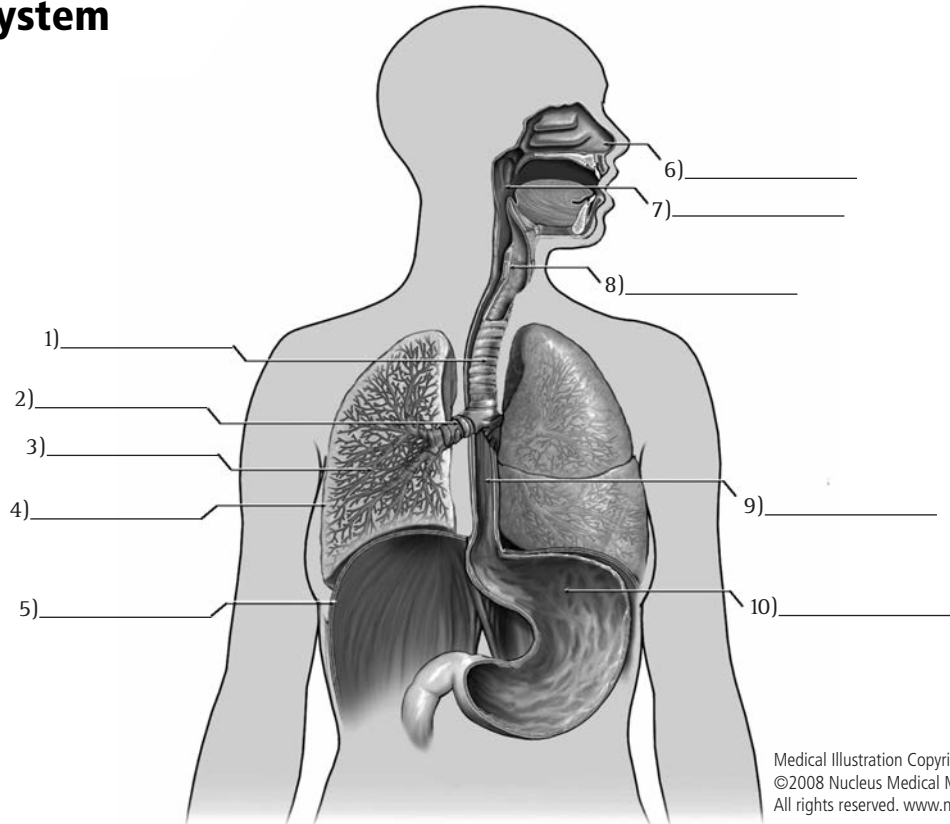


The Respiratory System

- Pharynx
- Esophagus
- Bronchiole
- Trachea
- Diaphragm
- Stomach
- Bronchus
- Right lung
- Larynx
- Nasal passage



Medical Illustration Copyright
 ©2008 Nucleus Medical Media,
 All rights reserved. www.nucleusinc.com

The Digestive System

- Appendix
- Gallbladder
- Transverse colon
- Esophagus
- Oral cavity
- Liver
- Duodenum
- Tongue
- Sigmoid colon
- Pancreas
- Oropharynx
- Ileum
- Stomach
- Cecum
- Anal canal/anus
- Jejunum
- Rectum
- Ascending colon

