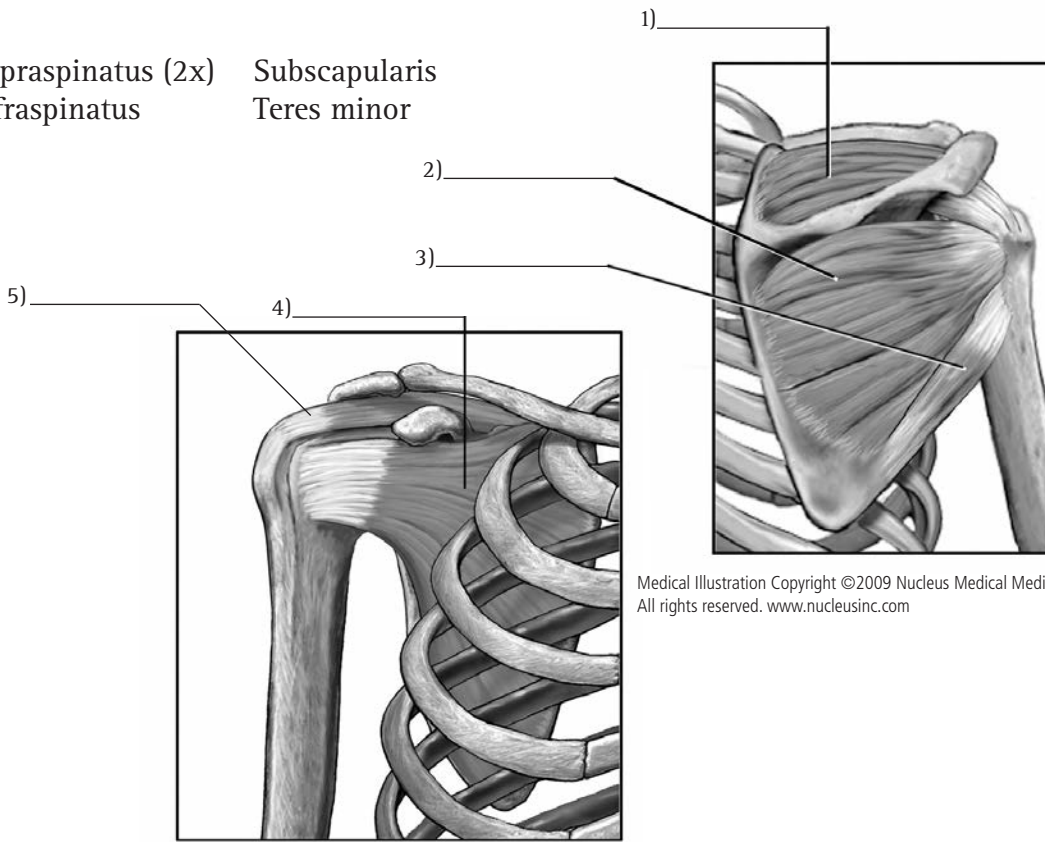
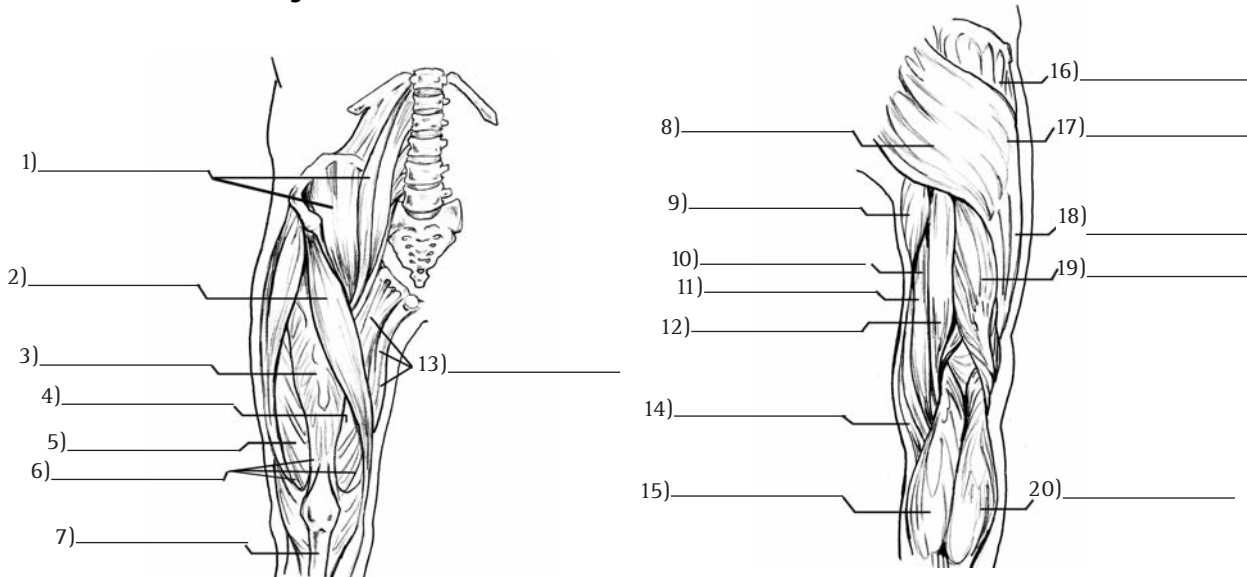


Rotator Cuff

Supraspinatus (2x)
Infraspinatus Subscapularis
Teres minor



Lower Extremity Muscles



Gracilis
Gluteus medius
Semitendinosus
Adductor group
Adductor magnus

Rectus femoris
Iliotibial band
Gluteus maximus
Vastus lateralis
Tensor fascia

Semimembranosus
Gastrocnemius (medial)
Gastrocnemius (lateral)
Biceps femoris
Patellar Ligament

Vastus medialis
Iliopsoas
Sartorius (2x)
Quadriceps